



Publisher homepage: www.universepg.com, ISSN: 2663-7529 (Online) & 2663-7510 (Print)

<https://doi.org/10.34104/ijavs.023.012026>

International Journal of Agriculture and Veterinary Sciences

Journal homepage: www.universepg.com/journal/ijavs

International Journal of
**Agriculture and
Veterinary Sciences**



Identification, Pathogenicity, Public Health and Economic Importance of Tapeworms of Poultry

Daniel Tamirat WeldeMariam^{1*}, Md. Raquibul Islam², Mahedi Hassan³, Saima Akter Bristy⁴, and Md. Khokon Hossain³

¹Dept. of Veterinary Public Health, Haramaya University College of Veterinary Medicine, Ethiopia; ²Healthcare Pharmaceuticals Ltd, Rajendrapur, Gazipur, Bangladesh; ³Dept. of Biochemistry and Molecular Biology, Gono Bishwabidyalay, Dhaka, Bangladesh; and ⁴Dept. of Microbiology, Gono Bishwabidyalay, Dhaka, Bangladesh.

*Correspondence: danitsehay21@gmail.com (Daniel Tamirat WeldeMariam, Department of Veterinary Public Health, Haramaya University College of Veterinary Medicine, Ethiopia).

ABSTRACT

Tapeworms of poultry are a group of cestodes that parasitize the intestinal tract of chickens and other birds. They cause economic losses due to reduced production, growth retardation, weight loss and mortality. In Ethiopia, several species of tapeworms have been reported in poultry, especially in free-range systems and low land areas. The most common genera are *Davainea*, *Hymenolepis*, *Amoebotaenia*, *Choanotaenia* and *Raillietina*. These tapeworms have complex life cycles that require arthropod or other invertebrate intermediate hosts, such as snails, beetles, ants and earthworms. The birds become infected by ingesting these intermediate hosts that contain the infective larval stage of the tapeworms. The larvae then attach to the mucosa of the intestine and change themselves to adult tapeworms that produce eggs or proglottids that are passed in the feces. Tapeworm infections can cause various clinical signs and pathological lesions in poultry, depending on the species, number and location of the worms. Some of the common signs are diarrhea, anorexia, emaciation, weakness, ruffled feathers, slow movement and rapid breathing. Some tapeworms can also cause intestinal blockage, hemorrhage, nodular growth, and catarrhal enteritis. Tapeworm infections can also predispose the birds to other diseases by impairing their immunity and nutrition. However, other chicken diseases may have similar symptoms and effects like tapeworm infections, so deferential diagnosis should be done in the laboratory level or at post-mortem examination. The treatment and control of tapeworm infections in poultry are challenging because of the presence of intermediate hosts that serve as sources of infection. Prevention of birds from contact with intermediate hosts is the most important step that should be taken in the control of tapeworm infection. This can be achieved by improving the hygiene and sanitation of the poultry houses and yards, providing clean water and feed, preventing access of wild birds and rodents that may carry intermediate hosts and using insecticides or biological agents to reduce intermediate host populations. Tapeworms of poultry are a significant problem in Ethiopia and other tropical countries where free-range systems and low land areas are common. They cause economic losses and affect the health and welfare of poultry. Therefore, more attention should be given to their identification, pathogenicity, public health and economic importance.

Keywords: Pathogenicity, Poultry, Economic importance of tapeworm, Identification, and Public health.

INTRODUCTION:

Tape worms of the poultry are flat, segmented and parasitic worms that belong to the class Cestoda. They
UniversePG | www.universepg.com

infect the intestinal tract of various domestic and wild birds, causing significant losses in production and health. In Ethiopia, tape worms of poultry are pre-

valent and pose a serious threat to the poultry industry and public health. According to a study by Abdo *et al.* (2022), the prevalence of tape worms of poultry in Ethiopia ranges from 11.8% to 100% depending on the region, season and management system. The most common species of tape worms of poultry in Ethiopia are *Raillietina tetragona*, *Raillietina echinobothrida*, *Raillietina cesticillus* and *Davainea proglottina* (Demis *et al.*, 2015; Belete *et al.*, 2016; Bogach *et al.*, 2020). These parasites can cause reduced weight gain, decreased egg production, intestinal obstruction, perforation and hemorrhage, and increased susceptibility to other diseases (Sarba *et al.*, 2019, Belete *et al.*, 2016). Moreover, some tape worms of poultry have zoonotic potential, meaning that they can infect humans as well.

Human infection can result from ingestion of raw or undercooked poultry meat or eggs containing the larval stages of the parasites. The symptoms of human infection may include abdominal pain, diarrhea, nausea, vomiting and allergic reactions (Sapp and Bradbury, 2020; CDC, 2013). Therefore, tape worms of poultry are not only a veterinary problem but also a public health concern. The economic impact of tape worms on poultry in Ethiopia is not well documented, but it is estimated that they cause considerable losses in terms of reduced productivity, increased mortality and treatment costs. Furthermore, tape worms of poultry can affect the quantity and safety of poultry products, reducing their market value and consumer acceptance (Panich *et al.*, 2022; Abdo *et al.*, 2022). Hence, tape worms of poultry are a major challenge for the development and sustainability of the poultry sector in Ethiopia.

Tape worms of poultry are flat-worms that belong to the class Cestoda. They are parasitic in nature and infect the intestinal tract of chickens, turkeys and other domestic birds. Tape worms of poultry can cause various diseases and disorders in their hosts, such as reduced growth, weight loss, diarrhea, anemia and intestinal obstruction. Tape worms of poultry also pose a significant threat to public health and economic development in Ethiopia. They can transmit zoonotic infections to humans who consume undercooked or contaminated poultry meat or eggs (Deneke *et al.*, 2022; Falculan, 2023; Feyera *et al.*, 2022).

They can also reduce the productivity and profitability of the poultry production farm, which is an important source of income and food security for many rural households in Ethiopia (Habte *et al.*, 2017). Therefore, it is essential to review on the identification, pathogenesis, epidemiology and control of tape worms of poultry in Ethiopia.

Literature of Review

Etiology of poultry tape worm

Poultry tape worm (*Raillietina spp.*) is a parasitic infection that affects chickens and other domestic birds. The tape worm has a complex life cycle that involves the intermediate host (usually an insect or a crustacean) and a definitive host, which is the bird (Jilo *et al.*, 2022).

Classification

The classification of poultry tapeworms is as follows (Abdo *et al.*, 2022). The infected birds with the tape worm release the eggs of tape worm through their feces and ingested by the intermediate host. Those eggs hatch and develop into the larvae (cysticercoids) inside the intermediate host. Then the bird eats the intermediate host and the larvae attach to the intestinal wall of the bird and grow into adult worms.

The adult worms can reach up to 1 meter in length and cause various symptoms such as weight loss, diarrhea, reduced egg production, anemia, and the intestinal obstruction (McDougald, 2020). The infection can be diagnosed by finding eggs or segments of the worm in the feces or by examining the intestines at necropsy (Alroy and Gilman, 2020). Over 1400 species of tapeworms have been described from poultry and different birds throughout the world. Of 193 genera belonging to 17 families that have been identified from birds and 45 species of 10 different genera were parasitize domestic fowl (Skoracki *et al.*, 2022, Demis *et al.*, 2015; Uddin *et al.*, 2022).

In Ethiopia, the major cestodes species recovered from the small intestine of chickens were *Amoebotaenia cuneata*, *Raillietina echinobothrida*, *Raillietina tetragona*, *Raillietina cesticillus*, *Davainea proglottina*, *Choanotaenia infundibulum*, *Hymenolepis cantaniana* and *Hymenolepis carioca* (Demis *et al.*, 2015).

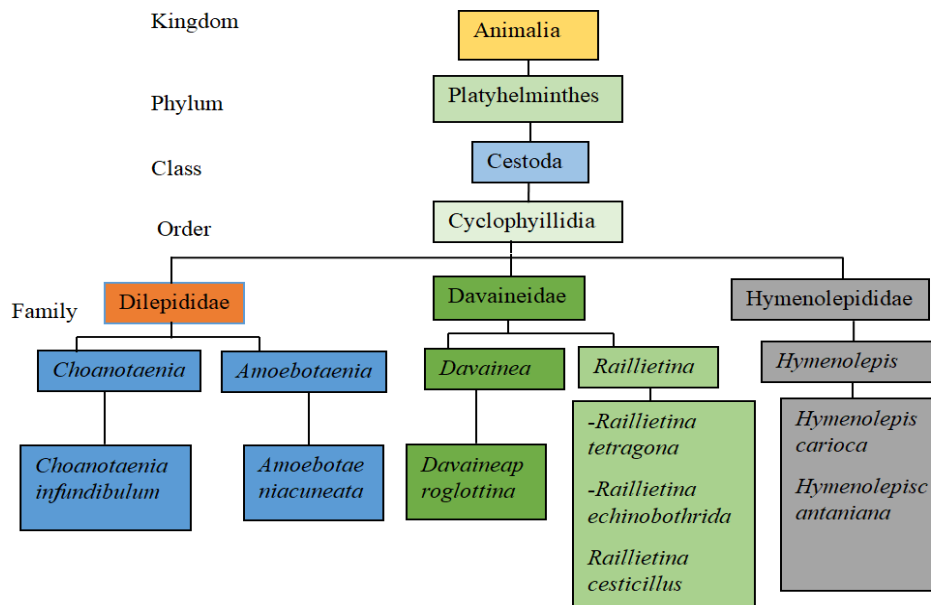


Fig. 1: Taxonomy of poultry tapeworms.

Identification

Tapeworms of poultry are flat, segmented worms that belong to the class Cestoda (Jilo *et al.*, 2022). They live in tract of the intestine of chickens, turkeys, and other birds, where they adhere themselves to the wall with their hook-like mouthparts. Tapeworms can cause weight loss, stunted growth, nutritional deficiencies, and increased susceptibility to infections or diseases in poultry (Panich *et al.*, 2022). Some tapeworms can also damage the intestinal wall and cause peritonitis or neurological signs (Caldrer *et al.*, 2022). There are many tapeworm species that can infect poultry, but some of the most common ones are *Davainea proglottina*, *Raillietina cesticillus*, *Raillietina tetragona*, and *Raillietina echinobothrida* (Salem *et al.*, 2022).

These tapeworms are the differ in size, shape, and distribution. *Davainea proglottina* is a small tapeworm (less than 4 mm long) that prefers the duodenum (the first part of the intestine) and it is the most serious tapeworm parasite of poultry in the United States (Jha, 2019). *Raillietina echinobothrida* is a large tapeworm (up to 30 cm long) that has a nodular appearance and is widely distributed throughout the country (Panich *et al.*, 2022). The indirect life cycle of tapeworms that involves intermediate hosts such as insects, or other invertebrates (ants, earthworms, etc.). Poultry gates infected by ingestion of these intermediate hosts that contain tapeworm larvae. Then the larvae grows into

UniversePG | www.universepg.com

adult tapeworms in the poultry's intestines and produce segments that contain eggs. These segments are shed in the feces and contaminate the environment. The intermediate hosts ingest the segments or eggs and become infected with tapeworm larvae. The identification of tapeworms in poultry is challenging due to their morphological similarity and complex life cycle. Molecular techniques, such as PCR and DNA sequencing, can provide more accurate and reliable identification of tapeworm species and their intermediate hosts (Panich *et al.*, 2022). However, these techniques are expensive and require specialized equipment and expertise. Therefore, more accessible and affordable methods for tapeworm identification in poultry, such as the rapid diagnostic tests or morphometric analysis were needed (Makwanise *et al.*, 2020).

Morphological identification

Morphological identification of poultry tape worm is an important method to diagnose and control the infection of this parasite in commercial chickens (Hassan *et al.*, 2023). Poultry tape worm, also known as *Raillietina echinobothrida*, is a cestode that belongs to the family *Davaineidae* (Lalchandama, 2009). It can cause weight loss, reduced egg production, and intestinal obstruction in chickens. Morphological identification of poultry tape worm involves observing the features of the scolex, proglottids, and eggs of the parasite under a microscope or by staining techniques

(Jha, 2019; Roy and Giri, 2015). The scolex of poultry tape worm is spherical and has four round suckers and a retractable rostellum with two rows of hooks. The proglottids are rectangular and have a well-developed cirrus pouch and 30-40 testes in each mature segment (Gholap *et al.*, 2022). The gravid proglottids contain 200-400 eggs that have an onchosphere with six hooks. Molecular phylogenetic identification based on 18s rRNA and ITS-2 gene sequences can also be used to confirm the species of poultry tape worm and its evolutionary relationship with other tapeworms (Zhang *et al.*, 2021). They have a scolex (the head) followed by a neck. The rest of the body is called the strobila consisting of a number of segments (proglottids) developing from the neck. Each segment contains male and female reproductive organs. The number of segments differs between species. The body is detached from the segments that are farthest from the neck as they mature. Numerous eggs are present in these gravid segments, and they are released into the environment with the feces (Jilo *et al.*, 2022). Immature, mature and gravid segments are present in the strobila. Immature proglottids are those that are closest to the head and neck; mature (adolescent) proglottids are those that are farther from the scolex and neck; and gravid larvae are those that are furthest from the scolex and neck. Gravid proglottids have male and female reproductive organs that have aged and degenerated to the point where only the uterus filled with eggs remains. The eggs are made up of a onchosphere (hexacanth embryo), a striated shell (embryophore), and the delicate membrane (madrigal, 2020). The rostellum, which resembles an anchor, may also be present. Typically, the rostellum has hooks that point backward and it uses these hooks to further anchor the tapeworm in the small intestine mucosa. The neck is a germinal or growth region that is immediately posterior to the scolex (Loos-Frank and Grecnis, 2016; Adebowale and Bamikole, 2023).

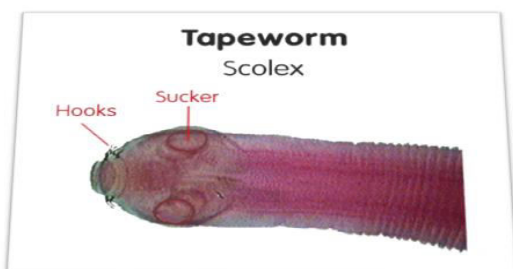


Fig. 2: Adult poultry tapeworm.

Identification of Species

The pathogenicity among various tapeworm species varies greatly. Prevention and control strategies may also differ depending on the tapeworm species. As a result, species identification is important (McDougald, 2020).

Raillietina tetragona: It was one of the largest and commonest of poultry tapeworms. Adults measure up to 25cm in length (Gamra *et al.*, 2015). *Raillietina tetragona* occurs in the posterior half of the small intestine of chickens and other birds throughout the world. The scolex is smaller than *the Raillietina echinobothridia*. The rostellum is armed with one or two rows of hooks and the suckers are oval in shape and also armed with 8-12 rows of minute hooks. The genital pores are usually unilateral and the uterus breaks in to capsules containing 6-12eggs. The cirrus sac is small (75-100mm), and more anterior in proglottids margin. The eggs are 25-50um in diameter (Amadi *et al.*, 2022).

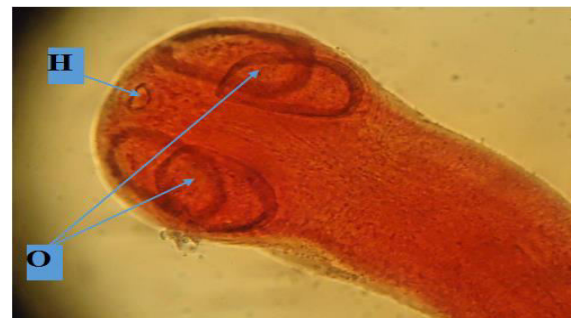

Fig. 3: Anterior end of *R. tetragona* from small intestine, showing a row of hooks (H), and oval suckers (O).

Raillietina echinobothrida: is the most pathogenic tapeworm among the *Raillietina* group. It occurs in the intestine of chicken and turkey. The length of this worm is about 25 centimeters. Both rostellum and suckers are armed with hooks. The eggs are found in the egg capsules in the gravid segments. This species resembles *Raillietina tetragona* but, differ in the following characters: The strobila is larger (34cm long by 4cm wide); the scolex has rounded suckers containing 200-250 hooks; genital pores are in the posterior half of the proglottid and gravid proglottids frequently loosen from each other in center, making a window-like arrangement not found in *Raillietina tetragona* (McDougald, 2020).

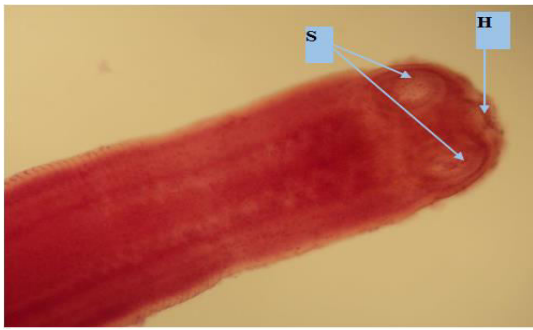


Fig. 4: Anterior end of *R. echinobothrida* from small intestine showing scolex with circular suckers (S) and the hooks (H).

Raillietina cesticillus: It is 4 cm, rarely 15 cm long. It has a large scolex with a wide rostellum armed with 400-500 small hooks. The suckers are inconspicuous and unarmed. The eggs, 75-88 μm in diameter, occur singly in egg capsules. This tapeworm is the most commonly found member of genus *Raillietina* and can be recognized easily from others by the absence of neck and a large scolex bearing wide rostellum (Ginhoux *et al.*, 2010, Abdullah, 2019). The scolex of this large robust tapeworm (up to 15cm long) embeds deeply in the mucosa of the duodenum or jejunum. A retractable piston acting as a double row of 300-500 hammer-shaped hooks on the distinctive, wide, flat rostellum draws in to an outer sleeve of the scolex to provide a firm grip on the mucosa. It has four unarmed weak suckers. The genital pores of this worm alternate irregularly. There are 20-30 testes posteriorly in proglottid. Mature eggs (75-88 μm in diameter) have two distinctive funnel-shaped filaments between the inner and middle membranes and occur singly in egg capsules (Demis *et al.*, 2015).

Davainea proglottina: This tapeworm is the smallest and the most pathogenic of the tapeworms that affect domestic fowl. It is about 0.5-3 mms long and has 4-9 segments. The predilection site for this worm is the duodenal loop of the small intestine and it may be recognized in the duodenal mucosa by protrusion of the gravid proglottids above the villi if the open intestine is floated in water. Both the rostellum and the suckers are armed with hooks. Genital pores are situated close to the anterior margin and alternate regularly (Sainsbury, 2009; Nandi, 2010). The eggs are 28-40 μm in diameter and occur singly in the egg capsule of the gravid proglottid. The only proglottid shed by

this parasite each day is a gravid one. Chickens become infected with *Davainea proglottina* after ingestion of infective slugs from the ground (Abdullah, 2019).




Fig. 5: Anterior end of *D. proglottina* showing increasing breadth (arrows) of each succeeding segment.

Amoebotaenia cuneata: is a small, slender, thread like worm of the small intestine of domestic fowl. The rostellum, which has a single row of 12-14 hooks, is armed but the suckers are unarmed. At the very anterior end of the proglottids margin, the genital pores typically alternate erratically, and 12-15 testes are arranged transversely in a single row across the posterior end of the proglottid. It is roughly triangular in shape, up to 20proglottids long, and 4mm long (Demis *et al.*, 2015).

Choanotaenia infundibulum: It is extremely white and noticeable attached to the upper portion of the small intestine of this large, robust, and white tapeworm of poultry (McDougald, 2020). Mature worms are about 23cm long. The suckers are unarmed but the rostellum is large with a single row of 16-22 hooks. Genital pores alternate irregularly; 25-60 testes are grouped in posterior portion of the proglottid. The segments of this worm are markedly wider posteriorly than anteriorly giving the worm a characteristic saw edged appearance. The eggs are with distinctive elongated filaments (Trasia, 2021). *Hymenolepis carioca*: The adult is slender and up to 8 cm long. The suckers unarmed; rostellar sac present; rostellum rudimentary; three testes usually in straight row, genital pores that are unilateral and situated anterior to the proglottid margin; an inner membrane enveloping the oncosphere elongated into a football shape with granular deposits at poles, embryonic hooks 10-12 μm . Several numbers of this extremely slender worm have been found in the duodenum of a chicken. The worm is so

slender (about 1mm in diameter) that hundreds of inconspicuous proglottids seem like a thread than a worm. An inner membrane enveloping the onchosphere is elongated in to a foot-ball shape with granular deposits at poles (McDougald, 2020).

Hymenolepis cantaniana: This short hymenolepid tape-worm has a maximum length of about 2cm and it superficially resembles longer *Hymenolepis carioca*. It is usually listed as unarmed but rostellar hooks have been described by investigators. Genital pores are unilateral, anterior to the middle of the proglottid (Yazwinski and Tucker, 2008).

Lifecycle

Generally poultry tapeworms with known life history require intermediate hosts for completion of the life cycle. Investigations have shown invariably that intermediate hosts of tapeworms have been invertebrates, such as beetles, flies, ants, snails, slugs, crustaceans etc. The type of intermediate host that serves a particular tapeworm in its successful transference, depends on the habitat of the avian host, e.g. terrestrial birds (chickens, turkey, guinea fowl, etc.), intermediate host must lead a terrestrial life or at least amphibious (Strasburg and Boone, 2022). Intermediate hosts may swallow individual eggs in the faecal mass or devour the entire proglottid after being attracted by odour or movement. Following ingestion, it hatches in the digestive tract and the liberated onchosphere penetrates the intestinal wall, and enters the body cavity. Hatching and penetration involves breast like movement of the hooks and secretion from the penetration glands as the parasite invades the body cavity (haemocoel) the intermediate host (Bandyopadhyay *et al.*, 2022). The hexacanth embryo develops into a white, bladder-like spherical body known as cysticercoid in the next several weeks. The cysticercoid usually remains alive in the invertebrate intermediate host and infective to the bird host for many months, e.g. *Raillietina cesticillus* retains its infectivity for five and half months. In a few life cycles, the cysticercoids survive ingestion by a auxiliary host (Cottingham *et al.*, 2022). Mechanical or chemical actions within the gut of the definitive host free the cysticercoid. The scolece vagenates, and attaches to the intestinal wall. The cyst wall degenerates and is lost, while the strobila proliferates from the neck region to form a

new tapeworm. Most tapeworms require 2-3 weeks prepatent period in the bird to mature and release the first proglottids in the faeces (Elwabhani, 2019).

Davainea proglottina: Several species of slugs and snails host the larval stages of *Davainea proglottina*. Gravid proglottids are found in the feces primarily in the afternoon or night. The gravid segments of adult tapeworms are shed with the birds' feces (usually one gravid segment per tapeworm per day). The gravid segments can ascend the vegetation because they are mobile. The gravid segments are consumed by the snails and slugs, and once they are digested, the eggs are released. In the body cavity of the intermediate hosts, the eggs then transform into cysticercoids. More than 1500 cysticercoids have developed along the digestive tract of susceptible slugs; where they have remained infective for more than 11 months. About 300 worms were found in one bird, and these tapeworms can live for up to three years (McDougald, 2020).

Raillietina tetragona: Cysticercoids develop in ants of the genera *Pheidole* and *Tetramorium*. After giving chickens cysticercoids, there must be a minimum prepatent period of 13 days to 3 weeks (Demis *et al.*, 2015).

Raillietina echinobothrida: As with *Raillietina tetragona*, numerous species of ants have been found naturally infected with cysticercoids. Concurrent infection with both *Raillietina echinobothrida* and *Raillietina tetragona* cysticercoids have been found in ants (Belete *et al.*, 2016).

Raillietina cesticillus: The intermediate hosts are beetles of the genera *Calathus*, *Amara*, *Pterostichus*, *Bradycellus*, *Harpalus*, *Poecilus*, *Zabrus*, *Anisotarsus*, *Choeridium*, *Caratacanthus*, and the *Stenophorus*. A minute histrid beetle (*Carcinospumilo*) is the natural intermediate host in broiler houses. More than 930 cysticercoids were found in a single ground beetle. After giving chickens cysticercoids, the pre-patent period lasts for 20 days (Mansur *et al.*, 2015).

Amoebotaenia cuneata (sphenoides): This tape-worm's intermediate hosts include a number of species of earthworms from the genera *Allotophora*, *Pheritima*, *Ocneroдрilus*, and the *Lumbricus*. Fowls acquire the

infection after rains when the earth worms come to the surface. The worms become adult in the fowl in 4 weeks (Cupo and Beckstead, 2019).

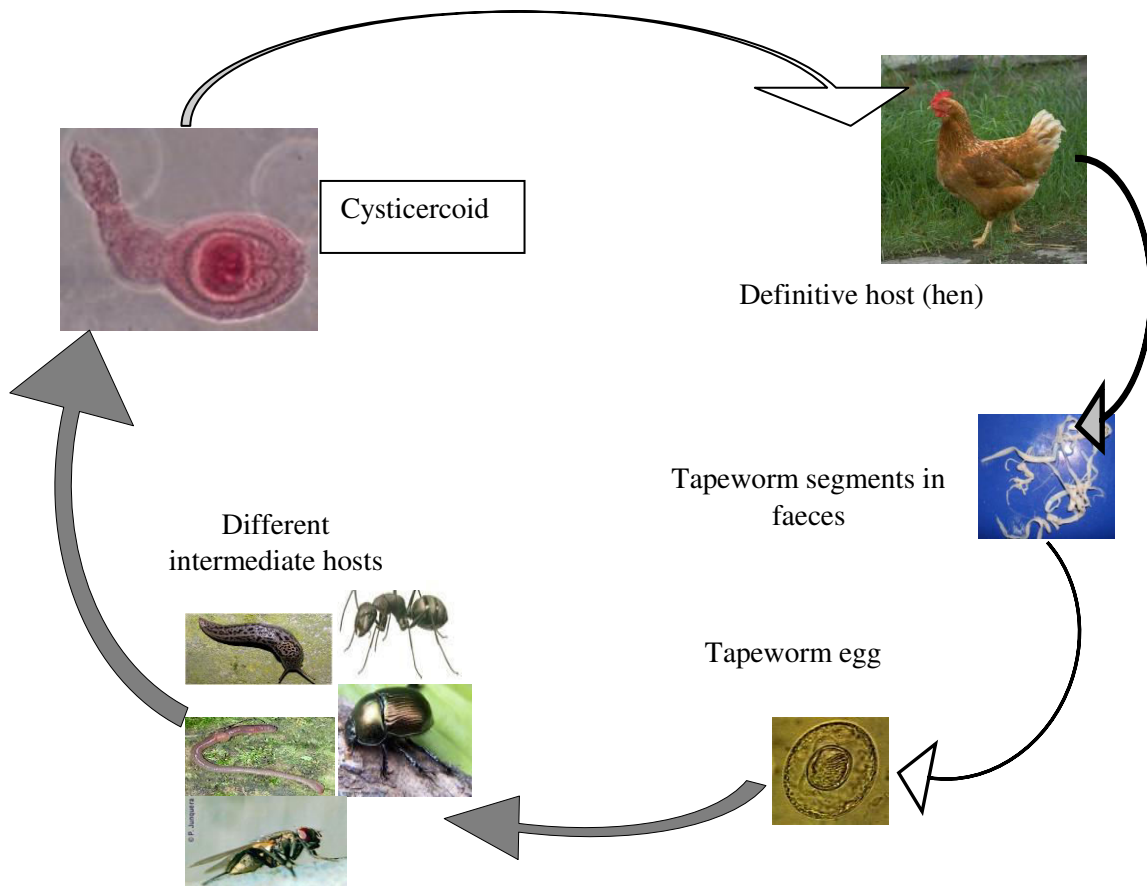


Fig. 6: Life cycle of poultry tapeworms; Source: (Demis *et al.*, 2015).

Choanotaenia infundibulum: This tapeworm has an indirect life cycle with domestic and wild birds as final host and house flies (*Muscadomestica*) and beetles of the genera *Geotrupes*, *Aphodius*, *Calathus* and *Tribolium* as intermediate hosts. Between infection and the first egg's shedding, or the prepatent period, there are 2 to 4 weeks (Michlmayr *et al.*, 2022). Stable flies and dung beetles serve as the intermediate hosts for the tapeworm *Hymenolepis carioca*. The cysticercoids are liberated after digestion of beetles or flies and develop to adult tapeworms in the chicken. Dung beetles (Scarabeidae) serve as intermediate hosts for the tapeworm *Hymenolepis contaniana*, a beetle may contain 100 cysticercoids or more. A unique larval development involves budding, which produces many cysticercoids from a single onchosphere. By eating beetles that contain cysticercoids, birds contract the infection. Following beetle digestion, the cysticercoids are released, and in the chicken, they mature into adult

tapeworms (Elwabhani, 2019).

Epidemiology

Host range

Numerous of cestode species have been reported from domestic and wild birds. They produce diseases in chickens, turkeys, ducks, geese, swans, guinea fowl, pigeons, pea fowl, ostriches, pheasants, quails and other birds (Scanes and Christensen, 2019).

Distribution

Tapeworms have cosmopolitan distribution, but they are more common in developing countries where chicken are reared in free-range. In many parts of Africa, Asia and Latin America, chicken are reared on an extensive system and sanitation is poorly developed. In such circumstances, the incidence of infection with tapeworms is high (Castro *et al.*, 2021). In Ethiopia, cestodes of poultry are more frequent in the low land areas and in the warmer seasons of the year

when intermediate hosts are abundant (Rukambile *et al.*, 2020). At higher altitudes, the infection level is low. This may be because the extreme low temperatures of the highland areas inhibit the development and survival of the intermediate hosts. Hence, the intermediate host has difficulty in surviving the colder environmental conditions of the highland areas whereas the warmer temperatures of the lowland areas create conducive conditions for their survival and transmission of the parasites (Caminade *et al.*, 2019).

Source of infection and route of transmission

Unlike round worms, infection of the tapeworms can never be attributed to consumption of worm eggs that have passed from the intestine in the manure. Before infecting a primary host, tapeworm eggs must first pass by the means of an intermediate host. Houseflies, snails, slugs, ants, beetles and earthworms are such intermediate hosts and many others are yet to be identified. Consumption of these intermediate hosts harboring the parasites in their larval stages results in infection of the birds (Assis and Pinto, 2023).

Pathogenicity

Tape worms of poultry are parasitic flatworms that belong to the class of Cestoda. They infect the intestines of various domestic and wild birds, causing a disease called cestodiasis. Some key points about tape worms of poultry are: Tapeworms are flat and segmented worms that parasitize the intestines of poultry and other animals. They have indirect life cycles that involve middle hosts such as beetles, flies, earthworms and grasshoppers. Poultry become diseased by ingesting these hosts that contain tapeworm larvae (McDougald, 2020). There are many types of tape-worms that can infect poultry, but they are generally not considered of the great pathogenicity, especially in modern poultry production systems. However, some tapeworms can cause significant harm to the health and productivity of poultry by competing for nutrients, damaging the intestinal wall, causing inflammation and peritonitis, and predisposing to the secondary infections (Ngongeh *et al.*, 2014, McDougald, 2020). *Raillietina cesticillus*, a tapeworm that lives on beetles, is the most dangerous type of tapeworm found in poultry. The mature tapeworm can reach a length of 12-13 cm. After consuming diseased beetles, which were themselves infected by bird droppings, infected

birds become infected (Belete *et al.*, 2016). Young chickens may experience stunted growth, adults may become emaciated, and hens may produce fewer eggs as a result of this tapeworm (Panarelli, 2024). This phenomenon is named "Nodular tapeworm disease" and may occur in heavy infections. In mature flocks, cestodes causes emaciation, especially if a severe infestation is made worse by malnutrition or immune-suppression (Elwahbani, 2019). Reduced growth, emaciation, and weakness are characteristics of chronic infections caused by *Raillietina* species. The most pathogenic from the three species is *Raillietina echinobothrida*. In this infection, the young forms of the parasite penetrate with their anterior end deeply into the mucosa and sub-mucosa of the duodenum, resulting in the formation of nodules and hyperplastic enteritis at the site of their attachment (Panarelli, 2024). The cestode-*Hymenolepis carioca* is thought to be the least pathogenic. However, in severe infections, clinical signs such as enteritis, diarrhea, anemia, and paleness of the comb and wattles, in addition to thickening of the intestine wall, can occur (Mangus *et al.*, 2021). In *Raillietina tetragona* infection, the intestinal wall is thrown into ridges of purplish color and the intestinal mucosa slough-off. *Raillietina cesticillus* is a common tapeworm found in chicken jejunum that causes intestinal villi degeneration and inflammation. Sugar and hemoglobin levels in affected birds are below normal (Babiker, 2020). Another tapeworm species that can cause neurological manifestations such as torticollis (wry neck) is *Davainea proglottina*, which has the housefly as its host. This tapeworm can cause peritonitis in the intestine to propagate to the brain and the sinuses.

Clinical Signs and Lesions

Intestinal worms affect birds by taking the required nutrients from the digestive system, resulting in depletion of nutrients. Enteric worms also disturb the organ function at sites where they grow and sometimes they produce toxic substances to damage the parts concerned. Due to decreased nutrient content, retarded growth and decline in production are the primary signs observed in birds. Furthermore, worms induce stress and predispose birds to other pathogenic organisms (Belete *et al.*, 2016). Clinical signs include boring plumage, slow movements, decreased weight gain, and

emaciation, dyspnea (difficulties in breathing), leg paralysis and death. Microscopically thickened mucosal membrane with hemorrhages, fetid mucus and necrosis are seen. The occurrence of the Cestodes, *Davainea proglottina*, is significant because it has been linked to hemorrhagic enteritis, that could complicate anemia caused by ecto-parasite (Belete *et al.*, 2016).

Catarrhal enteritis, hemorrhage, intestinal obstruction and nodular growths in heavy infection. Capillary congestion, lymphocytic and eosinophilic infiltrations, fibrosis and proliferation in the gut are the important microscopic changes associated with the tapeworm infection (Bodnar *et al.*, 2020).

Table 1: Pathogenicity of several significant poultry tapeworms (Source: Pattison, 2009).

Tapeworms species	Intermediate Host	Definitive Host	Degree of Pathogenicity	Length of mature Worm (mm)
<i>Raillietinae chinobothridia</i>	Ant	Chicken	Moderate to severe	200-340
<i>Raillietina tetragona</i>	Ant	Chicken	Medium to severe	100-250
<i>Raillietina cesticillus</i>	Beetle	Chicken	Low or harmless	6-150
<i>Davainea proglottina</i>	Slug and Snail	Chicken	Severe	4
<i>Amoebotaenia cuneata</i>	Earth worm	Chicken	Mild	3
<i>Choanotaenia infundibulum</i>	Beetle and House flies	Chicken	Moderate	50-200
<i>Hymenolepis cantaniana</i>	Dung beetle	Chicken	Mild or harmless	20
<i>Hymenolepis carioca</i>	Dung beetle and Stable flies	Chicken	Unknown	40

Diagnosis

Diagnosis of poultry Cestodes usually is made at necropsy. A postmortem examination of a representative number of the flock is the most satisfactory means of diagnosis since only a burden of parasites may be assessed, but also the species may be determined. Cestodes are usually readily visible in the intestine of affected birds. But, whenever possible, they should be removed intact so that their head, mature and gravid segments are all available for examination (IJsseldijk *et al.*, 2019). Eggs or individual segments (proglottids) recently hidden in the feces or collected from the intestine during post-mortem may be examined under the microscope. Microscopic examination does not only help in establishing diagnosis but also identifies different species of chicken tapeworms (Panich *et al.*, 2022).

Differential diagnosis

The eggs and proglottids of tapeworms should be identified for differentiating one species from the other (Alroy and Gilman, 2020). In the case of *Raillietina echinobothrida* (nodular worm), a protuberance or the nodule develops in the intestinal wall at the site of attachment of each worm. This sometimes confuses with tuberculosis. Hence, tuberculosis may be suspected in such fowls if no worm is present in the nodule (Sultana *et al.*, 2021).

Treatment

Chemical treatment of infected birds is possible, but a number of these require 24 hours prior starvation of the bird, and so this naturally disrupts egg production in mature birds. Products such as Praziquantel 10mg/kg, Neclosamide 100mg/kg are effective against tapeworms (Jilo *et al.*, 2022). Albendazole and mebendazole may be given at the proportion of 20-30ml of suspension per 100 birds for one day as top dressing on the feed or in drinking water and at the proportion of 50mg per bird in the feed or in drinking water (Jana *et al.*, 2023). But, the use of drugs for removal of tapeworms from chicken is only a temporary means of solving the problem if the invertebrate hosts were still present as sources of the infection. Therefore, treatment should be associated with control measures against the intermediate hosts (Decru *et al.*, 2020).

Control and Prevention

Control over infection simply relies upon breaking the reproductive means of the tapeworm, by eradicating the intermediary hosts. Slug and snail bait, usually containing met aldehyde, must therefore be applied around the perimeter of the house (Beyene *et al.*, 2014). Control of *Davainea* and *Raillietina* is dependent on treating infected birds with an anthelmintic such as Neclosamide and butyrate and destroying slugs and snails whenever possible (Elwahbani, 2019). Preven-

tion of birds from contact with invertebrate hosts is the most important step that should be taken in the control of tapeworm infection. These are best achieved by strict sanitation and management. Sanitation requires complete cleaning of poultry houses and good management indicates that the flock should be checked periodically for the occurrence of worms (Habte *et al.*, 2017). Controlling insects and keeping wild birds out of poultry houses are very important measures. Raising birds in confinement or on wire reduces infection by worms. Control measures are not possible in free range birds. Affected birds should be treated first by wormicide and wormstat drugs before taking up preventive measures. It is also necessary to have the right approach of eliminating intermediate hosts as removing worm only will lead to further out-breaks (Clark and Kimminau, 2017; Rahman *et al.*, 2019).

Droppings should be removed from the overnight housing and the free range compound, and then properly disposed. New arrivals to the flock should be dewormed and quarantined in cages or baskets for at least 15 days before joining the flock. The house should be disinfected for every two months and feeders and drinkers have to be cleaned properly and birds should be separated in to different age groups (Bhinda *et al.*, 2016). The feed used for poultry must be insect free feed. The use of Malathion or other insecticides should be carried out routinely to control flies, other insects and ants. Met aldehyde bait was used for slugs. Beetles and earthworms are more difficult to control but rotation of ranges may be helpful (Andrade *et al.*, 2021).

Economic Importance

Parasitism is a major threat to poultry production, causing substantial financial losses in the production of meat and eggs. Gastrointestinal parasitic infection in poultry has a negative economic impact on production parameters, particularly in backyard or the farmyard flocks, as opposed to confinement rearing, which is used in current commercial farming (Hussain, 2022). Tape-worms affect chicken by taking the required substance from the body and also disturb the absorptive organs at sites where they grow and result in low feed conversion efficiency. The amount of feed needed to produce one kilogram of live weight in broilers and a dozen of eggs in layers increases as these worms

compete for the feed (Churchil and Jalaludeen, 2022). Birds require longer time to attain market size and to reach at their laying age. Worm-infected chickens' sale prices and turnover rate fall, while treatment and production costs rise. The time spent in managing these birds is also another area of expense. Heavy parasitic infections cause stress that lowers the chickens' resistance to other infections (Abd El-Hack *et al.*, 2022). Furthermore, cestode infections in domestic poultry cause delayed development, reduced egg production, dropped weight gain, and, in severe cases, cause mortality (Jilo *et al.*, 2022).

Public health importance

Tape worms of poultry are parasitic flatworms that infect the intestines of poultry. They can cause serious health problems for the poultry and the humans who consume their eggs or meat. Some of the common symptoms of tape worm infection in poultry are weight loss, reduced egg production, diarrhea, anemia and intestinal obstruction (Abdo *et al.*, 2022). Tape worms can also transmit diseases such as cysticercosis and echinococcosis to humans, which can affect the brain, liver and intestine (WHO, 2020). Therefore, it is significant to prevent and control tape worm infection in poultry for public health reasons. One of the ways to prevent tape worm infection in poultry is to maintain good hygiene and sanitation in the poultry farms. This includes cleaning and disinfecting the coops, feeders and waterers regularly, removing fecal matter and dead birds promptly, and avoiding keeping with wild birds or rodents that may carry tape worm eggs (FAO, 2017). Another way to prevent tape worm infection is to use anthelmintic drugs that kill or expel the worms from the poultry. These drugs should be administered according to the instructions of a veterinarian and with proper. Tapeworms of poultry are parasitic worms that belong to the class Cestoda and have a flat, segmented body that can grow up to several inches long. They live in the intestines of chickens, turkeys, and other birds, where they use their hook-like mouthpieces to bind themselves to the intestinal wall. Tapeworms have a complicated life cycle that includes a transitional host, such as an insect, a rodent, or a snail, which consumes the tapeworm larvae from the infected bird's feces. Inside the inter-mediate host, the eggs hatch into larvae that form cysts in its tissues. When a bird eats the

intermediate host, it becomes infected with the tapeworm (Mujahid, 2017). Tapeworms can cause various problems for poultry and humans. They can reduce the feed efficiency, growth rate and egg production of the birds by competing for nutrients and damaging the intestinal lining. They can also cause diarrhea, weight loss, anemia and weakness in severe cases. Some tapeworms can infect humans if they consume raw or undercooked poultry meat or the organs that contain cysts. This can cause nausea, vomiting, pain in the abdomen, and obstruction of the intestines (Sarba *et al.*, 2019). *Davainea proglottina* is a tapeworm that can cause intestinal destruction and peritonitis in chickens. If it spreads to the head and sinuses, it can also cause neurological symptoms such as torticollis (Shivaprasad, 2014). Tapeworms of poultry are common in Ethiopia and other countries where poultry are raised under free-range or backyard conditions (Himmel *et al.*, 2021). They can be prevented by improving the hygiene and sanitation of the poultry environment, reduced the use of human feces as fertilizer, controlling the intermediate hosts and treating the infected birds with anthelmintic drugs (Zhou *et al.*, 2020). Tapeworms of poultry are important parasites that affect both animal and human health (Ahmad *et al.*, 2023).

CONCLUSION AND RECOMMENDATIONS:

Tapeworms are parasitic flatworms that infect the intestines of poultry and other animals. They cause various diseases and disorders in the host, such as reduced growth, weight loss, diarrhea, anemia, intestinal obstruction, and mortality. Tapeworm infections can be diagnosed by examining the feces or the intestine for the presence of eggs or proglottids. For removal of tapeworms the use of drugs is usually not effective if the intermediate hosts are still present in the environment. Therefore, treatment should be combined with control measures directed against intermediate hosts. Tapeworms also pose a public health risk as some species can infect humans through the consumption of the undercooked or raw poultry meat or eggs. Tapeworms have a significant economic impact on the poultry production in Ethiopia and other developing countries, as they reduce the productivity and quality of poultry products and increase the treatment cost and prevention. The identification of tapeworms in poultry is challenging due to their morphological similarity and

complex life cycle. Molecular methods, such as the polymerase chain reaction (PCR) and the sequencing of DNA, can provide more accurate and reliable identification of tapeworm species and their intermediate hosts. However, these techniques are expensive and require specialized equipment and expertise. Therefore, more accessible and affordable methods for tapeworm identification in poultry, such as rapid diagnostic tests or morphometric analysis.

The pathogenicity of tapeworms in poultry depends on several factors, such as the species and number of parasites, the age and immune status of the host, the nutritional and environmental conditions, and the presence of other pathogens. Tapeworms can cause direct damage to the intestine and interfere with nutrient absorption and digestion. They can also induce inflammatory and immune responses that may affect the host's health and performance. Moreover, tapeworms can act as vectors or reservoirs for other pathogens, such as bacteria, viruses, or protozoa, that can cause secondary infections or co-infections in poultry. The public health and economic importance of tapeworms in poultry is evident from the high prevalence of these parasites in Ethiopia and other countries. Tapeworms can cause zoonotic diseases in humans, such as cysticercosis or hydatidosis, that can result in serious complications or death. Tapeworms can also reduce the quantity and safety of poultry products, such as meat or eggs, that can affect consumer preference and demand. Furthermore, tapeworms can cause reduction in the poultry production due to decreased production efficiency, increased mortality rate, increased veterinary expenses, and reduced market value. Therefore, it is recommended that effective measures should be taken to prevent and control tapeworm infections in poultry in Ethiopia and other countries. These measures include:

- 1) Improving the hygiene and sanitation of poultry farms and slaughterhouses to prevent contamination of feed, water, litter, or equipment with tapeworm eggs or intermediate hosts.
- 2) Educating farmers and consumers about the transmission routes and risks of tapeworm infections in poultry and humans and promoting good practices for the handling, processing, cooking, and storing poultry products.

- 3) Implementing regular screening and monitoring programs for tapeworm infections in poultry using appropriate diagnostic methods and reporting the results to relevant authorities.
- 4) Applying appropriate anthelmintic treatments for infected poultry according to the recommendations of veterinarians or experts.
- 5) Developing and implementing integrated pest management strategies to control the intermediate hosts of tapeworms, such as insects or rodents, using biological, chemical, or physical methods.
- 6) Supporting research and innovation on tapeworm identification, pathogenicity, epidemiology, prevention, and control in poultry and humans.

ACKNOWLEDGMENT:

I would like to thank my advisor Dr. Addis Mesfin and Dereje Tamirat for their incalculable and unreserved advice, intellectual guidance, and devotion of time in correcting this senior seminar paper.

CONFLICTS OF INTEREST:

There are no conflicts of interest in this work.

REFERENCES:

- 1) Abd El-Hack, Ahmed, A. E. and El-Kott, A. F. (2022). Alternatives to antibiotics for organic poultry production: types, modes of action and impacts on bird's health and production. *Poultry science*, 101696. <https://doi.org/10.1016/j.psj.2022.101696>
- 2) Abdo, S., Abadura, S. Z. & Nair, S. P. (2022). The Study on Prevalence of Gastrointestinal Helminths in Chickens, Bale Zone, Dalomana District, Southeast Ethiopia. *Journal of World's Poultry Science*, 1, 16-22.
- 3) Abdullah, S. (2019). Revalence and morphological studies of gastrointestinal helminths of backyard chicken in bangladesh. Dept. Of microbiology and parasitology,123,234,123457.
- 4) Adebowale A., and Bamikole A. (2023). Socio-economic effects of Oyo state government COVID-19 palliatives on poultry farmers. *Int. J. Agric. Vet. Sci.*, 5(6), 137-154. <https://doi.org/10.34104/ijavs.023.01370154>
- 5) Ahmad, S., Humak, F., and Ashraf, T. (2023). Phytochemicals as alternative anthelmintics against poultry parasites: A review. *Agrobiological Records*, 12, 34-45. <https://doi.org/10.47278/journal.abr/2023.015>
- 6) Alroy, K. A. & Gilman, R. H. (2020). Tapeworm infections. Hunter's tropical medicine and emerging infectious diseases. *Elsevier*, 345,789.
- 7) Amadi, E., Eze, E., and Chukwuma, S.(2022). Evaluation of Parasites as Veritable Indicators of Faecal Escherichia coli Contamination of Surface Waters: A Case Study of Adada River, Enugu State, Nigeria. *American J. of Water Resources*, 10, 1-8. <https://doi.org/10.12691/ajwr-10-1-1>
- 8) Andrade, C., Guillocheau, S. & Pillon, O. (2021). A real-world implementation of a nationwide, long-term monitoring program to assess the impact of agrochemicals and agricultural practices on biodiversity. *Ecology and Evolution*, 11, 3771-3793.
- 9) Assis, J. C. & Pinto, H. A.(2023). Biomphalaria straminea as an Intermediate Host of a Renal Trematode Species of the Genus Tanaisia (Trematoda: Eucotylidae) in Brazil. *Acta Parasitologica*, 1-6.
- 10) Babiker, E. K. M. A. (2020). Prevalence and intensity of intestinal worms in chicken (gallus domesticus) in khartoum state. *Alneelan Unverslty*.
- 11) Bandyopadhyay, P., Das, N. & Chattopadhyay, A. (2022). Introduction to Parasitic Helminthes and Cestoda. Biochemical, Immunological and Epidemiological Analysis of Parasitic Diseases. *Springer*. <https://doi.org/10.1007/978-981-16-4384-2>
- 12) Belete, A., Addis, M. and Ayele, M. (2016). Review on major gastrointestinal parasites that affect chickens. *Journal of Biology, Agriculture and Healthcare*, 6, 11-21.
- 13) Beyene, K., Bogale, B. and Chanie, M. (2014). Study on effects and occurrence of nematodes in local and exotic chickens in and around Bahir Dar, Northwest Ethiopia. *American-Eurasian J. of Science Research*, 9, 62-66.
- 14) Bhinda, R., Gora, A. D., Aechra, S. & Jhajhara, G. (2016). Backyard poultry farming - a source of livelihood for rural farmers, 65,78,99.
- 15) Bodnar, Y., Voloshyn, V. & Gargin, V. (2020). Essentials of pathology, 5(23), 235.
- 16) Bogach, M., Stoyanova, V. & Palii, A.(2020). The influence of hydro-meteorological conditions on

- the spread of chicken cestodiasis. *Regulatory Mechanisms in Biosystems*, **11**, 414-418.
- 17) Caldrier, S., Motta, L. and Angheben, A. (2022). Soil-Transmitted Helminths and Anaemia: A Neglected Association Outside the Tropics. *Microorganisms*, **10**, 1027.
<https://doi.org/10.3390/microorganisms10051027>
- 18) Caminade, C., McIntyre, K. M. and Jones, A. E. (2019). Impact of recent and future climate change on vector-borne diseases. *Annals of the New York Academy of Sciences*, **1436**, 157-173.
- 19) Castro, P. D. J., Gilleard, J. S. & Kaplan, R. M. (2021). Multiple drug resistance in hookworms infecting greyhound dogs in the USA. *Inter J. for Parasitology: Drugs and Drug Resistance*, **17**, 107-117.
- 20) Churchil, R. R. and Jalaludeen, A. (2022). Duck farming: opportunities, constraints and policy recommendations. *Duck Production and Management Strategies*. Springer, **17**, 21-35, 345.
- 21) Clark, S. & Kimminau, E. (2017). Critical review: future control of blackhead disease (histomoniasis) in poultry. *Avian Diseases*, **61**, 281-288.
- 22) Cottingham, S. L., Walden, H. D., and Campos-Krauer, J. M. (2022). Gastrointestinal Parasites of Farmed White-tailed Deer (*Odocoileus virginianus*) in Florida: WEC453/UW498, 10/2022. *ED-15*, 2022.14
- 23) Cupo, K. L. & Beckstead, R. B. (2019). *Heterakis gallinarum*, the cecal nematode of gallinaceous birds: a critical review. *Avian diseases*, **63**, 381-388. <https://doi.org/10.1637/0005-2086-63.3.381>
- 24) Decru, E., Mul, M., & Sleenckx, N. (2020). Possibilities for IPM Strategies in European laying hen farms for improved control of the Poultry Red Mite (*Dermanyssus gallinae*): details and state of affairs. *Frontiers in Veterinary Science*, **7**, 565866.
- 25) Demis, C., Anteneh, M. and Basith, A. (2015). Tapeworms of poultry in Ethiopia: A Review. *British Journal of Poultry Science*, **4**, 44-52.
- 26) Deneke, T. T., Bekele, A., and Hodge, C. (2022). Milk and meat consumption patterns and the potential risk of zoonotic disease transmission among urban and peri-urban dairy farmers in Ethiopia. *BMC public health*, **22**, 222.
- 27) Elwabhani, H. E. H. (2019). Prevalence of Gastrointestinal Worms Infections of Poultry in Atbara Locality River Nile State-Sudan. Sudan University Of science and technology.
- 28) Falculan KN. (2023). Risk management determinants among small scale poultry raisers in Simara island Philippines. *Int. J. Agric. Vet. Sci.*, **5**(4), 88-94.
<https://doi.org/10.34104/ijavs.023.088094>
- 29) Feyera, T., Ruhnke, I. and Walkden-Brown, S. W. (2022). Worm control practices on free-range egg farms in Australia and anthelmintic efficacy against nematodes in naturally infected layer chickens. *Veterinary Parasitology: Regional Studies and Reports*, **30**, 100723.
- 30) Gamra, O., Antia, R. & Falohun, O. (2015). Intestinal cestodes of poultry *Raillietina echinobothrida* and *Choanotaenia infundibulum* infection in a commercial Japanese quail (*Coturnix coturnix japonica*) farm in Apomu, Osun State, Nigeria. *Scientific Journal of Zoology*, **4**, 20-25.
- 31) Gholap, A. B., Wankhede, J. & Pulate, M. (2022). A new species of genus *Amoebotaenia alokni* sp. nov. From *Gallus gallus domesticus* from Ahmednagar district, (MS) India. *J. of Scientific Research*, **66**.
<https://doi.org/10.37398/JSR.2022.660316>
- 32) Ginhoux, F., Greter, M., & Stanley, E. R. (2010). Fate mapping analysis reveals that adult microglia derive from primitive macrophages. *Science*, **330**, 841-845.
- 33) Habte, T., Amare, A., & Wigley, P. (2017). Guide to chicken health and management in Ethiopia: For farmers and development agents. *ILRI Manual*, 23467.
- 34) Hassan, T. A., El-Gayer, A. K. & Sallam, N. H. (2023). Morphological and Molecular Studies of Ecto-and Endoparasites Infested Chicken in Ismailia Province, Egypt. *Journal of Advanced Veterinary Research*, **13**, 352-359.
- 35) Himmel, T., Harl, J., & Weissenböck, H. (2021). A citizen science-based survey of avian mortality focusing on haemosporidian infections in wild passerine birds. *Malaria Journal*, **20**, 1-13.
- 36) Hussain, A. (2022). Ichthyo parasitic fauna, Its prevalence and economical loss: A review. *Animal Science Journal*, **13**, 01-09.

- 37) Ijsseldijk, L. L., Brownlow, A. C. & Mazzariol, S. (2019). European best practice on cetacean post-mortem investigation and tissue sampling. <https://doi.org/10.31219/osf.io/zh4ra>
- 38) Jana, A., Bhaskar, T. & Ghosh, D.(2023). Poultry Waste Biorefinery: Opportunities for Sustainable Management. *Biotic Resources.CRC Press*.
- 39) Jha, A. K. (2019). Histopathological studies of tape-worm *Raillietina tetragona* (Molin, 1858) from the gastrointestinal of indigenous chicken (*Gallus domesticus* L.) farming in Kirtipur, Nepal. *International Journal of Veterinary Sciences and Animal Husbandry*,4, 01-06.
- 40) Jilo, S. A., Abadula, T. A., & Nair, S. P.(2022). Review on epidemiology, pathogenesis, treatment, control and prevention of gastrointestinal parasite of poultry.
- 41) Lalchandama K. (2009). On the structure of *Raillietina echinobothrida*, the tapeworm of domestic fowl. *Sci Vis*, 9, 174-182.
- 42) Loos-Frank, B. & Grensis, R. K. (2016). Parasitic worms. *The Biology of Parasites*, 182.
- 43) Madrigal, P. A. M. P. (2020). Phylum Platyhelminthes: Class Cestoda. *Markell and Voge's Medical Parasitology-10th Sea Ed*, 211.
- 44) Makwanise, T., Dube, S. & Sibula, M. (2020). Molecular characterization of *Raillietina* isolates from the gastrointestinal tract of free range chickens (*Gallus gallus domesticus*) from the southern region of Zimbabwe using the 18S rDNA gene. *Veterinary Parasitology: Regional Studies and Reports*, 20, 100389.
- 45) Mangus, L. M., França, M. S., and Wolf, J. C. (2021). Relevant background lesions and conditions in common avian and aquatic species. *ILAR journal*, 62, 169-202. <https://doi.org/10.1093/ilar/ilab008>
- 46) Mansur, F., Luoga, W., & Behnke, J. (2015). The anthelmintic efficacy of natural plant cysteine proteinases against *Hymenolepis microstoma* in vivo. *Journal of Helminthology*, 89, 601-611.
- 47) Mcdougald, L. R. (2020). Internal parasites. *Diseases of poultry*, 1157-1191.
- 48) Michlmayr, D., Alves De Sousa, L., and Rasmussen, L. D. (2022). Incubation period, spore shedding duration, and symptoms of *Enterocytozoon bieneusi* genotype C infection in a food-borne outbreak in Denmark, 2020. *Clinical Infectious Diseases*,75, 468-475. <https://pubmed.ncbi.nlm.nih.gov/34791090/>
- 49) Mujahid, T. (2017). Prevalence of intestinal helminth parasites of chicken (*Gallus gallus domesticus* Linnaeus, 1758) in Lalitpur district, Nepal. Department of Zoology.
- 50) Ngongeh, L., Chiejina, S. and Lawal, A. (2014). Prevalence of gastrointestinal helminth infections in slaughtered chickens reared in the Nsukka area of Enugu State, Nigeria. *IOSR J. Agric. Vet. Sci*,7, 51-54.
- 51) Panarelli, N. C. (2024). Infectious Diseases of the Gastrointestinal Tract. *Gastrointestinal and Liver Pathology*, 243-298.
- 52) Panich, W., Nak-On, S. and Chontanarith, T. (2022). High-performance triplex PCR detection of three tapeworm species belonging to the genus *Raillietina* in infected poultry. *Acta Tropica*, 232, 106516.
- 53) Rahman MA, Uddin ME, and Ahmed R. (2019). Isolation, identification, and antibiotic sensitivity pattern of *Salmonella* spp from locally isolated egg samples. *Am. J. Pure Appl. Sci.*, 1(1), 1-11. <https://doi.org/10.34104/ajpab.019.019111>
- 54) Roy, B. & Giri, B. R. (2015). α -Viniferin-induced structural and functional alterations in *Raillietina echinobothrida*, a poultry tapeworm. *Microscopy and Microanalysis*, 21, 377-384. <https://doi.org/10.1017/S1431927614014603>
- 55) Rukambile, E., Chengula, A., and Jong ejan, F. (2020). Poultry ecto-, endo-and hae-moparasites in Tanzania: a review. *Austin J. Vet. Sci. Anim. Husb*,7, 1066.
- 56) Salem, H. M., Salaeh, N. M., and Attia, M. M. (2022). Incidence of gastrointestinal parasites in pigeons with an assessment of the nematocidal activity of chitosan nanoparticles against *Ascaridia columbae*. *Poultry Science*, 101, 101820.
- 57) Sapp, S. G. and Bradbury, R. S. (2020). The forgotten exotic tapeworms: a review of uncommon zoonotic Cyclophyllidea. *Parasitology*,147, 533-558.
- 58) Sarba, E. J., Bayu, M. D., and Borena, B. M. (2019). Gastrointestinal helminths of backyard chickens in selected areas of West Shoa Zone

- Central, Ethiopia. *Veterinary Parasitology: Regional Studies and Reports*, **15**, 100265.
- 59) Scanes, C. G. & Christensen, K. D. (2019). Poultry science, *Waveland Press*, **32**,47-65,236. <https://www.waveland.com/browse.php?t=745>
- 60) Shivaprasad, H. (2014). Differential diagnoses for diseases of poultry based on organ systems and other outlines. *Avian Pathology*. California Animal Health and Food Safety Laboratory System, Tulare Branch School of Veterinary Medicine. *University of California, Davis*, **5**(23), 324.
- 61) Skoracki, M., Sikora, B., & Hromada, M. (2022). Mite Fauna of the Family Syringophilidae (Acari-formes: Prostigmata) Parasitizing Darwin's Finches in Galápagos Archipelago. *Diversity*, **14**, 585.
- 62) Strasburg, M. & Boone, M. D. (2022). Can predators stabilize host - parasite interactions? Changes in aquatic predator identity alter amphibian responses and parasite abundance across life stages. *Ecology and Evolution*, **12**, e9512.
- 63) Sultana, S., Sultana, N., & Khan, M. A. H. N. A. (2021). Zoonotic diseases appeared to be a major hurdle to successful deer farming in Bangladesh. *Veterinary World*, **14**, 2462.
- 64) Trasia, R. F. (2021). Current Finding of Helminth Morphology Cause Infectious Disease. *J. Al-Azhar Indonesia Seri Sains dan Teknologi*, **6**, 76.
- 65) Uddin ME, Sultana S, and Mahmud S. (2022). Non-biotech student's perception of biotechnology and its applications in a university theology faculty student's: a brief survey study. *Int. J. Agric. Vet. Sci.*, **4**(6), 116-129. <https://doi.org/10.34104/ijavs.022.01160129>
- 66) Yazwinski, T. A. & Tucker, C. A. (2008). Nematodes and acanthocephalans. *Diseases of poultry*, **12**, 1025-1056.
- 67) Zhang, D., Wu, G., & Huo, N. (2021). Molecular phylogenetic identification and morphological characteristics of *Raillietina echinobothrida* (Cestoda: Cyclophyllidae: Davaineidae) in commercial chickens in North China. *Parasitology Research*, **120**, 1303-1310. <https://doi.org/10.1016/j.sjbs.2023.103784>
- 68) Zhou, Z., Shen, B. & Bi, D. (2020). Management of pathogens in poultry. *Animal Agriculture, Elsevier*, **31**, 47-69,129.

Citation: WeldeMariam DT, Islam MR, Hassan M, Bristy SA, and Hossain MK. (2024). Identification, pathogenicity, public health, and economic importance of tapeworms of poultry. *Int. J. Agric. Vet. Sci.*, **6**(1), 12-26.

<https://doi.org/10.34104/ijavs.024.012026>

